

# Xenografting of sheep testis tissue and isolated cells as a model for preservation of genetic material from endangered ungulates

Lucía Arregui<sup>1,2</sup>, Rahul Rathi<sup>1</sup>, Susan O Megee<sup>1</sup>, Ali Honaramooz<sup>1</sup>, Montserrat Gomendio<sup>2</sup>, Eduardo R S Roldan<sup>2</sup> and Ina Dobrinski<sup>1</sup>

<sup>1</sup>Center for Animal Transgenesis and Germ Cell Research, New Bolton Center, University of Pennsylvania, Kennett Square, Pennsylvania 19348, USA and <sup>2</sup>Reproductive Biology and Ecology Group, Museo Nacional de Ciencias Naturales, Consejo Superior de Investigaciones Científicas, 28006 Madrid, Spain

Correspondence should be addressed to I Dobrinski; Email: [dobrinsk@vet.upenn.edu](mailto:dobrinsk@vet.upenn.edu)

A Honaramooz is now at Veterinary Biomedical Sciences, University of Saskatchewan, Saskatchewan, Canada

## Abstract

Recovery of germ cells could be an option for preservation of the genetic pool of endangered animals. In immature males, xenografting of testis tissue provides the opportunity to recover sperm from these animals. In adult animals, xenografting has been less successful, but *de novo* morphogenesis of functional testis tissue from dissociated testis cells could be an alternative. To assess the potential use of these techniques in endangered bovid species, the domestic sheep was used as a model. Testes from 2-week-old lambs were grafted as tissue fragments or cell suspensions into nude mice. Grafts were recovered at 4, 8, 12 and 16 weeks post grafting. For isolated cells, two additional time points at 35 and 40 weeks after grafting were added. In addition, to analyse the possible effect of social stress among mice within a group on the development of the grafts, testis tissue grafts were recovered 13 weeks post grafting from mice housed individually and in groups. Complete spermatogenesis occurred in sheep testis xenografts at 12 weeks, similar to the situation *in situ*. Isolated sheep testis cells were able to reorganize and form functional testicular tissue *de novo*. Housing mice individually or in groups did not have any effect on the development of xenografts. Xenografting of testis tissue might be useful to obtain sperm from immature endangered ungulates that die prematurely. Testis tissue *de novo* morphogenesis from isolated cells could open interesting options to recover germ cells from mature males with impaired spermatogenesis.

*Reproduction* (2008) **136** 85–93

## Introduction

When a member of an endangered species dies, its potential contribution to the genetic information of the species is lost. In a sexually mature male, it is sometimes possible to collect and cryopreserve spermatozoa before or after death, and these sperm cells can be used later for assisted reproduction (Roldan *et al.* 2006). However, preservation of spermatozoa is not an option in sexually immature males. Since *in vitro* culture of immature testis cells to mature spermatozoa has so far not been completely successful (Parks *et al.* 2003), xenografting of testis tissue as an *in vivo* culture system provides an interesting option. Xenografting of testis tissue from immature males of different mammalian species into immunodeficient mice has resulted in complete spermatogenesis (Honaramooz *et al.* 2002a, 2004, Schlatt *et al.* 2002, Shinohara *et al.* 2002, Oatley *et al.* 2004, Snedaker *et al.* 2004, Rathi *et al.* 2006). The advantage of xenografting is that it is the only technique to obtain sperm from immature testis tissue. The production of sperm per gram of testis in pig grafts was

comparable with that in the donor species (Honaramooz *et al.* 2002a) and spermatozoa recovered from testis grafts of different mammalian species were functional and able to fertilize by intra-cytoplasmic sperm injection (ICSI; Honaramooz *et al.* 2002a, 2004, Schlatt *et al.* 2003).

Cats have been used as models for endangered felids (Snedaker *et al.* 2004) and there is one brief report of xenografting of testis tissue from an endangered species, the Javan banteng (Honaramooz *et al.* 2005), although, in the latter, complete spermatogenesis was not achieved. Currently, there are 115 species of bovids under some degree of threat according to the Red List of Threatened Species (IUCN 2006, [www.iucnredlist.org](http://www.iucnredlist.org)), and they could benefit from the technique of xenografting (Paris & Schlatt 2007). Most studies on xenografting with bovid testis tissue have been done using bull tissue (Oatley *et al.* 2004, 2005, Rathi *et al.* 2005, Schmidt *et al.* 2006, Arregui *et al.* 2008, Huang *et al.* 2008), while few have been performed on goat (Honaramooz *et al.* 2002a, Arregui *et al.* 2008) or sheep tissue (Dobrinski *et al.* 2003, Zeng *et al.* 2006). However, more than 80% of the

endangered bovid species are closer to the subfamily Caprinae than Bovinae (Hernández Fernández & Vrba 2005, IUCN 2006) and sheep or goats could be better models for these species.

While xenografting of immature testis tissue presents a novel opportunity to preserve the genetic potential of sexually immature individuals, testis tissue grafting has been much less successful for tissue from sexually mature donors (Schlatt *et al.* 2002, 2006, Geens *et al.* 2006, Rathi *et al.* 2006, Arregui *et al.* 2008). One reason for this difference in developmental potential of testis fragments from immature compared with mature males may lie in the inability of Sertoli cells from adult testes to proliferate after grafting into a mouse host. It may be possible to recombine the germ cells from an adult testis with testicular somatic cells from a healthy immature donor to apply the xenografting approach to the conservation of germ cells from adult males with impaired spermatogenesis or outside the breeding season. Recently, *de novo* morphogenesis of functional testis tissue from dissociated testes cells has been described as an alternative to testis tissue xenografting to study the role of different cell populations during testicular organogenesis (Gassei *et al.* 2006, Honaramooz *et al.* 2007, Kita *et al.* 2007). While grafting of rat testis cells to mouse hosts after *in vitro* culture led to tubular morphogenesis, it did not support germ cell differentiation (Gassei *et al.* 2006). Complete tissue morphogenesis and spermatogenesis were accomplished after grafting of isolated porcine, mouse or rat testis cells into mice (Honaramooz *et al.* 2007, Kita *et al.* 2007). Application of this novel approach to sheep could open interesting options for conservation of germ cells from endangered ungulate species.

Mice carrying testis xenografts are maintained for several months to allow complete spermatogenesis to occur. Depending on colony management and experimental design, mice can be housed individually or in groups. House mice (*Mus musculus*) typically live in groups (Latham & Mason 2004), and there is evidence that mice prefer a cage with other individuals rather than being housed alone (Van Loo *et al.* 2004); also, single housing can cause physiological and behavioural problems (Würbel 2001, Fitchett *et al.* 2006). However, male mice housed in groups establish a social hierarchy by aggression that has been reported to correlate with the serum androgen levels in social animals (Machida *et al.* 1981). This in turn could affect diverse reproductive parameters. Group housing of male mice can lead to lowered sperm motility in socially inferior individuals (Koyama & Kamimura 1999). However, it is not known if housing xenograft recipient mice individually or in groups will affect graft development.

Therefore, the aims of this study were (1) to analyse the timing of testis tissue maturation and the onset of spermatogenesis in xenografts of testis tissue from young sheep as a model species for endangered ungulates in comparison with testicular maturation

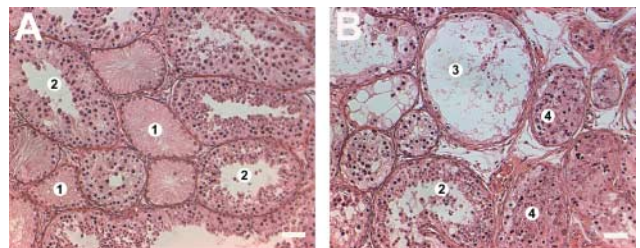
*in situ*, (2) to investigate *de novo* morphogenesis of testicular tissue from isolated ovine testis cells and (3) to assess whether social interactions between recipient mice affect graft development.

## Results

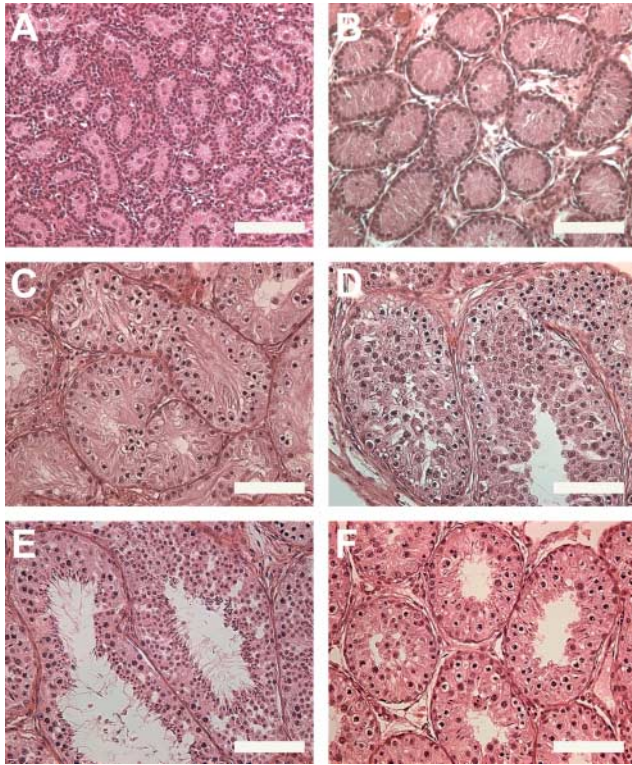
### Testis tissue grafting

Seminiferous tubules in donor and graft tissue were assessed and they were categorized based on the presence of Sertoli cells only, or on the presence of various differentiated germ cells; partially degenerated tubules as well as dilated tubules were also identified (Fig. 1). At the time of grafting of testis tissue from 14-day-old lambs, the percentage of seminiferous cords containing gonocytes was  $65.0\% \pm 1.4$  ( $n=2$ ). The percentage of round tubule cross-sections containing one, two or three gonocytes was  $48.7\% \pm 2.2$ ,  $14.8\% \pm 3.0$  and  $1.5\% \pm 0.6$  respectively (Fig. 2A). The total percentage of grafts recovered was  $95.7\% \pm 2.7$ . The seminal vesicle and graft weights per time point are shown in Fig. 3. Seminal vesicle weight was higher than 200 mg at all time points indicating that grafts secreted physiological amounts of bioactive testosterone. Weight of the grafted tissue increased fourfold between the time of grafting and recovery at 4 weeks and another fourfold by 16 weeks after grafting. Histological examination showed that at 4 weeks after grafting, germ cells had not begun meiotic differentiation and lumen formation had not yet occurred in any of the tubules, although the diameter of tubules was larger than in donor tissue (Figs 2B and 4). Spermatogonia were present in  $42.7\% \pm 3.0$  of the tubules, mostly in tubules at the periphery of the grafted tissue. The number of spermatogonia per tubule was  $2.1 \pm 0.1$ , the number of Sertoli cells per tubule was  $24.6 \pm 0.9$  and the number of spermatogonia per 100 Sertoli cells was  $8.7 \pm 0.7$ .

At 8 weeks post grafting,  $31.5\% \pm 8.1$  of seminiferous tubules contained pachytene spermatocytes, and tubular lumen had developed (Figs 2C and 4). In some grafts, the tubules with spermatocytes were in the periphery of the grafts while the tubules in the centre contained Sertoli



**Figure 1** Histological appearance of the categories used to classify seminiferous tubules of sheep testis tissue xenografts. (A) Sertoli cell only tubules (1) among those with differentiated germ cells (2) in a graft at 16 weeks post grafting. (B) Graft 16 weeks after transplantation showing tubules with differentiated germ cells (2), dilated (3) and partially degenerated (4) tubules. Scale bar = 100  $\mu\text{m}$ .



**Figure 2** Histological appearance of donor, graft and control tissue. (A) donor tissue from a 14-day-old Suffolk lamb; graft at (B) 4, (C) 8, (D) 12 and (E) 16 weeks post grafting; and (F) control tissue from 12-week-old Suffolk ram. Scale bar=100 µm.

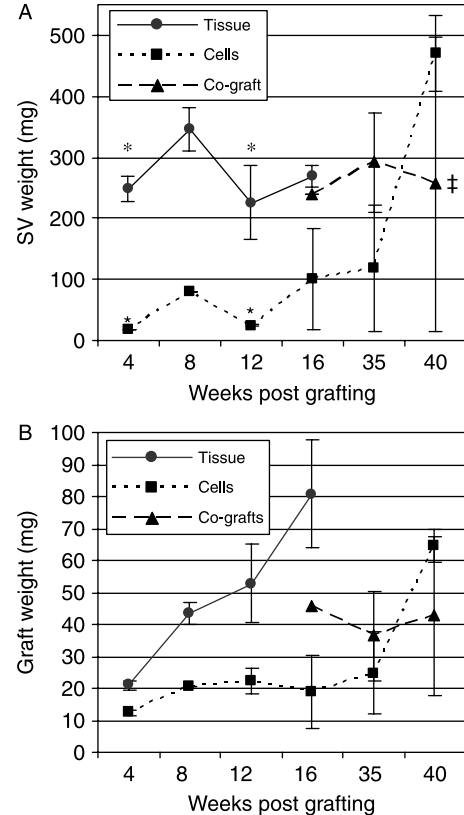
cells only. The percentage of tubules with spermatogonia had increased significantly ( $P=0.008$ ) to  $69.8\pm 6.7$ , and  $33.0\pm 2.5$  spermatogonia per 100 Sertoli cells were found at this time point. A mean of  $6.2\pm 0.5$  spermatogonia and  $18.8\pm 0.8$  Sertoli cells were present per tubule.

By 12 weeks after grafting, elongated spermatids were present in  $4.9\pm 2.4$  of tubules, tubular dilation had occurred in  $1.7\pm 0.8$  and  $0.3\pm 0.3$  were classified as partially degenerated (Figs 2D and 4). Tubules with elongated spermatids increased to  $18.8\pm 5.5$  by 16 weeks after grafting, dilated tubules to  $4.7\pm 2.9$  and partially degenerated tubules to  $6.9\pm 6.4$  (Figs 2E and 4). Tubules without differentiated germ cells were observed between those that contained differentiated germ cells (Fig. 1A).

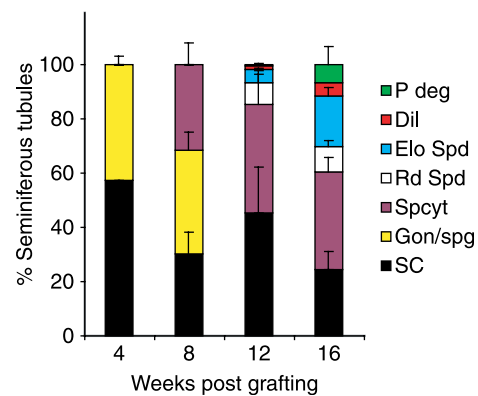
**Control tissue and comparison with grafted tissue**

At 12 weeks of age, the Suffolk testis tissue contained  $30.7\pm 6.8$  of tubules with elongated spermatids (Fig. 2F). No dilated or partially degenerated tubules were observed in the control tissue.

When comparing grafted tissue with tissue obtained from control sheep, it has to be taken into account that the transplanted tissue was already 2 weeks old



**Figure 3** (A) Seminal vesicle and (B) graft weights in mice with tissue, isolated cell, and tissue co-grafts at different times after grafting. Results are means  $\pm$  S.E.M. In tissue grafts,  $n=5, 6, 6$  and  $6$ ; in isolated cells grafts,  $n=2, 1, 2, 2, 2$  and  $2$ ; and in co-grafts,  $n=1, 2$  and  $2$ . SV, seminal vesicle. \*Indicates differences ( $P<0.05$ ) within time points. \*Seminal vesicle weights of the two mice with co-grafts at 40 weeks after grafting were noticeably different (16.2 and 496.7 mg respectively).



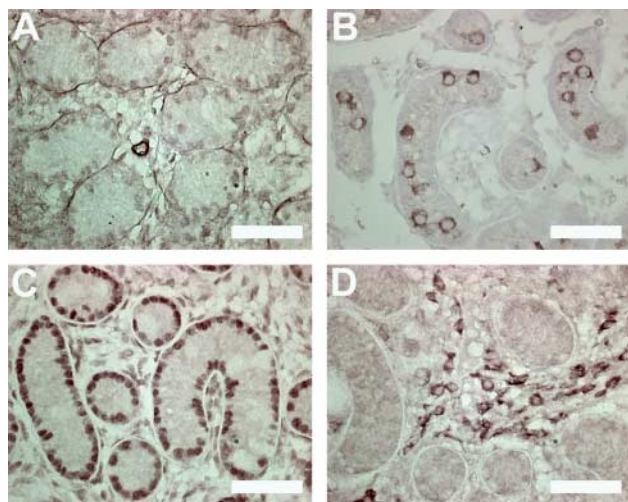
**Figure 4** Percentage of seminiferous tubules with most advanced germ cell type in testis tissue xenografts per time point. P deg, partially degenerated tubules; Dil, dilated tubules; Elo Spd, elongated spermatids; Rd Spd, round spermatids; Spcyt, pachytene spermatocytes; SC, Sertoli cells only; and Gon/spg, gonocytes or spermatogonia. Results are means  $\pm$  S.E.M.

when grafted. Nevertheless, after transplantation the proliferation of the tissue is retarded and germ cell division rate decreases until blood supply has been completely restored (Rathi *et al.* 2005).

At 12 weeks, both the control tissue and the grafts presented elongated spermatids as the most advanced germ cell. When percentages of every type of tubules were compared control testis tissue had fewer tubules with Sertoli cells only ( $P=0.044$ ), and more tubules with round spermatids ( $P=0.044$ ) and elongated spermatids ( $P=0.040$ ) than grafted tissue. Similar results were found when grafts at 16 weeks were compared with control tissue at 12 weeks: grafts had more tubules with Sertoli cells only ( $P=0.044$ ) and a lower percentage of tubules with round spermatids ( $P=0.046$ ) than the control tissue. There was no difference in the tissue development between grafts recovered at 12 and 16 weeks after grafting ( $P>0.05$ ).

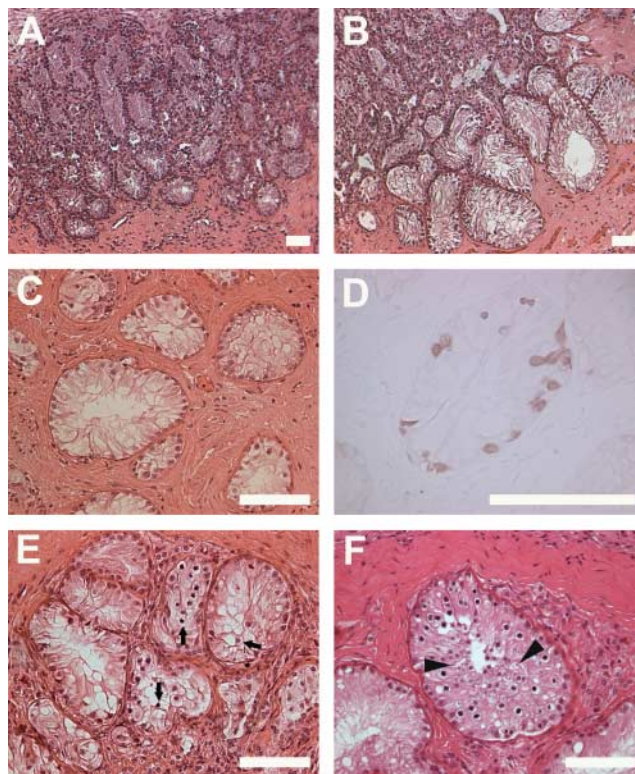
### Isolated cell grafting

Although enzymatic digestion is designed to remove most of the interstitial cells, some peritubular myoid cells and Leydig cells will remain in the cell suspension (Honar-amooz *et al.* 2007). At the time of transplantation, the cell pellets contained  $1.27\% \pm 0.50$  germ cells,  $55.47\% \pm 5.19$  Sertoli cells,  $6.13\% \pm 0.92$  myoid cells and  $4.60\% \pm 1.39$  Leydig cells. Cell types were identified by immunocytochemistry using cell type-specific antibodies. Specificity of the antibodies was confirmed on donor sheep testis tissue (Fig. 5). The total percentage of grafts recovered was  $92.0\% \pm 14.9$  ( $n=12$  mice). The weights of seminal vesicles and grafts are shown in Fig. 3. The seminal vesicle weight was higher in mice carrying tissue grafts than in those carrying grafts formed *de novo* from isolated cells at 4, 8 and 12 weeks post grafting ( $P=0.021$ ) but was



**Figure 5** Cell-type-specific immunohistochemistry in 14-day-old sheep testis tissue (A)  $\alpha$ -smooth muscle actin for myoid cells, (B) VASA for germ cells, (C) GATA4 for Sertoli cells and (D) P450scc for Leydig cells. Scale bar = 50  $\mu$ m.

similar at 16 weeks ( $P>0.05$ ). Histological analysis at 4 weeks post grafting revealed that seminiferous tubules formed in the periphery of the graft and began tubule formation in the centre of the graft (Fig. 6A). General appearance of the *de novo* formed grafts did not change by 8, 12 or 16 weeks after grafting in both isolated cells grafted alone or co-grafted with tissue, with cell cords in the centre of the grafts and tubules in the surrounding area. However, tubules became wider and more isolated with time (Fig. 6B and C). No differentiated germ cells were found at 4, 8, 12 and 16 weeks after surgery. Immunohistochemistry for protein gene product 9.5 (PGP 9.5) showed staining outside the tubules at 4 and 8 weeks post grafting, but at 16 weeks after grafting spermatogonia were found inside a few tubules formed from cells grafted alone or with tissue (Fig. 6D). At 35 weeks after surgery, the histology of the grafts was similar, but some tubules contained pachytene spermatocytes in grafts formed from isolated cells co-grafted with tissue (Fig. 6E). At 40 weeks post grafting, complete spermatogenesis was found in isolated cells grafted alone (Fig. 6F), while no differentiated germ cell could be found in co-grafts.



**Figure 6** Histological appearance of grafts generated *de novo* from isolated cells at (A) 4 weeks after grafting, (B) 8 and (C) 16 weeks post grafting, (D) germ cells localized by immunohistochemistry for PGP 9.5 at 16 weeks after grafting, (E) isolated cells co-grafted with tissue at 35 weeks post grafting and (F) isolated cell graft at 40 weeks post grafting. Pachytene spermatocytes are indicated with arrows and elongated spermatids with arrowheads. Scale bar = 100  $\mu$ m.

### Housing of male mice

The donor testes transplanted consisted of seminiferous cords containing somatic Sertoli cells only ( $49.6\% \pm 1.8$ ) or with one ( $42.3\% \pm 0.5$ ), two ( $7.4\% \pm 1.2$ ) or three ( $0.7\% \pm 0.1$ ) gonocytes per round section. One mouse housed in a group became ill and lost weight, and no grafts were recovered; therefore, data from this animal were not used. In the histological analyses of grafts, no differences were found in the percentage of tubules with Sertoli cells only, round spermatids, elongated spermatids, degenerated tubules and dilated tubules; however, the percentage of tubules with pachytene spermatocytes as the most advanced germ cell was statistically higher in mice kept alone ( $P=0.029$ ,  $55.9\% \pm 3.7$  in mice housed alone and  $39.5\% \pm 7.2$  in mice housed in group). When all of the tubules with differentiated germ cell were considered together, no differences were found ( $P>0.05$ ). The percentage of recovered grafts and the weights of the mice, seminal vesicles and grafts were not different between mice housed individually or in groups (Table 1).

### Discussion

Testis tissue from sexually immature sheep is able to develop complete spermatogenesis when grafted ectopically into a mouse host, and the first elongated spermatids appear at the same time in grafts and in the intact animal. We reported earlier that time to appearance of the first elongated spermatids in the seminiferous tubules was shortened in testis xenografts from pigs, rhesus monkeys and sheep when compared with the donor species (Honaramooz *et al.* 2002a, 2004, Dobrinski *et al.* 2003, Zeng *et al.* 2006). In our previous work in sheep, we found that at 3 months post grafting, complete spermatogenesis occurred in the xenografts, similar to what we found in the present experiment (Dobrinski *et al.* 2003, Zeng *et al.* 2006). The different conclusions could be due to the different source for control data. Our previous report compared the findings in the xenografts to reports in the literature that the first elongated spermatids and sperm in sheep appeared between 5 and 6 months after birth (Gier & Marion 1970). However, elongated spermatids can be found, when assessed histologically, in 12-week-old Suffolk rams as observed in the present study.

Although the time to production of haploid germ cells is similar in grafts and in intact testis tissue, the grafts

contained more tubules with Sertoli cells only and fewer tubules with round and elongated spermatids than the control tissue. Therefore, xenografts and intact tissue *in situ* completed spermatogenesis at the same time but the developmental state of the grafts at 12 weeks was less mature, than the control tissue at the same time point.

At 16 weeks post grafting, the grafts still contained more tubules with Sertoli cells only and fewer tubules with round spermatids than the control tissue. The lack of tubules with differentiated germ cells at all time points could be due to an initial loss of germ cells from the donor tissue when it was grafted as was reported previously (Rathi *et al.* 2005). In sheep grafts, 20% of tubules had lost spermatogonia in the first 4 weeks after grafting, although at 8 weeks the percentage of tubules with spermatogonia was comparable with that observed *in situ*.

In intact testis tissue from various mammalian species, the percentage of tubules with Sertoli cells only decreases rapidly when post-meiotic germ cells appear, and the percentage of tubules with round and elongated spermatids increases. These changes were less pronounced in the grafts. In addition, the percentage of tubules with spermatocytes and round spermatids in the grafts remained almost constant once they appeared, and no differences were found between grafts at 12 and 16 weeks after grafting. Therefore, it appears that the beginning of spermatogenesis in every seminiferous tubule occurs slowly and independently from the surrounding tubules in the xenograft, while, *in situ*, the onset of spermatogenesis occurs more uniformly in all tubules. In support of this hypothesis, we observed (1) differences in the timing of onset of germ cell differentiation between the peripheral and the central area of the graft and (2) variability between adjacent tubules in the stage of germ cell differentiation in the grafts (Fig. 1A) but not in the intact testis tissue *in situ*.

Two reasons could explain this fact: (1) factors supporting the development of the tubules are not available uniformly to all tubules and/or (2) tubules are not equally receptive to stimulatory signals. Grafted tissue experiences a period of ischaemia after transplantation. During this initial period, the periphery of the graft is more accessible to diffusion, and the new vessels will arrive earlier to this area. In addition, the distribution of these new vessels and diffusion inside the graft may lack uniformity. Once complete vascularization is established, all tubules will receive blood supply although

**Table 1** Body weight, seminal vesicle weight, graft weight and graft recovery in mice housed individually or in groups.

	Individual $n=8$	Group $n=7$
Body weight	$31.4 \pm 1.0$ (28.7–36.2)	$31.1 \pm 1.6$ (22.3–35.0)
SV weight	$290.0 \pm 45.1$ (19.2–423.0)	$279.6 \pm 51.2$ (14.4–425.2)
Graft weight	$74.5 \pm 11.2$ (12.9–112.2)	$63.4 \pm 14.8$ (1.3–116.6)
Graft recovered (%)	$100 \pm 0.0$	$91.1 \pm 7.1$ (50–100)

Results are means  $\pm$  s.e.m. (ranges). No statistical differences were found between mice housed individually or in groups.

some were exposed longer or earlier to some factors, and the developmental stage could be different. Also, this difference in the maturation status of the tubules could be inherent to the tissue. For example, differential response to gonadotrophin treatment due to different maturation status of the Sertoli cells was observed between testis xenografts from 3- and 6-month-old rhesus monkeys (R. Rathi, W. Zeng, S. Megee, A. Conley, S. Meyers & I. Dobrinski, unpublished observations).

When a cell suspension was prepared from lamb testis by enzymatic digestion and implanted underneath the skin of nude mice, the isolated cells were able to reorganize in cords and tubules, and complete spermatogenesis was found 40 weeks after grafting. In addition, when isolated cells were co-grafted with testis tissue, spermatocytes were found at 35 weeks after grafting, earlier than in isolated cells grafted alone. *De novo* morphogenesis of seminiferous tubules was demonstrated previously with neonatal pig Sertoli cells grafted under the kidney capsule of mice (Dufour *et al.* 2002) and with cultured rat cells xenografted subcutaneously (Gassei *et al.* 2006). Recently, we reported that complete spermatogenesis occurred at 30 weeks post grafting of isolated cells from piglet testis (Honaramooz *et al.* 2007). Similarly, functional spermatids also appeared in testis tissue formed *de novo* from isolated mouse and rat testis cells grafted ectopically to mouse hosts (Kita *et al.* 2007). Sheep isolated cell grafts completed spermatogenesis later than in the animal *in situ* and also later than in tissue grafts, similar to what was observed in pig isolated cell grafts. When isolated cells are grafted they undergo a spatial reorganization to form new tissue. The different cell types, including Leydig cells, have to form functional three-dimensional cell associations whereas in tissue grafts these are already formed. In mice with grafts of isolated cells and tissue, the weight of the seminal vesicles was always high (>200 mg), due to the production of testosterone by Leydig cells from the tissue grafts while production of testosterone in *de novo* formed tissue from isolated cells occurs later. By 35 weeks post grafting, grafts formed *de novo* from isolated cells grafted alone produced enough testosterone to support initiation of germ cell differentiation. This delay in germ cell differentiation could potentially be overcome by supplementation of testosterone. The later onset of spermatogenesis in isolated sheep cells grafts compared with those from pig testis cells, where complete spermatogenesis can be found 30 weeks after grafting (Honaramooz *et al.* 2007), could be due to the smaller percentage of germ cells after enzymatic digestion in the sheep isolated cell suspension (1.3%) compared with those isolated from pig testes (4.5%). Also, this small number of spermatogonia harvested after enzymatic digestion of lamb testis could explain the low efficiency of spermatogenesis in *de novo* formed sheep testis tissue.

Grafts recovered from mice housed alone presented more tubules with spermatocytes. However, no

statistical differences were found in any other type of differentiated germ cell. Therefore, different housing conditions for nude mice do not appear to have an effect on the development of the grafts. Also, the production of testosterone (measured as seminal vesicle weight) between isolated and grouped mice and among the grouped mice was not different. This fact could be due to the peaceful behaviour of this strain of mice compared with other mouse strains that display a higher degree of aggression. This observation is important for colony management and comparison with different experiments. Colony management in different research centres could be different or several experiments could have diverse experimental designs. Even in a xenografting experiment, sometimes mice will have to be removed from groups to avoid aggression. It is therefore important that the results of testis xenograft development are comparable between mice housed individually and in groups.

The best timing for retrieval of mouse sperm from mouse tissue grafts has been established (Schlatt *et al.* 2003), but no study has yet reported the timing of the highest sperm production in xenografts. Although the xenografts are viable for over 1 year after grafting (Honaramooz *et al.* 2002a, Snedaker *et al.* 2004) dilated tubules appeared, at least in some species, at the same time as post-meiotic cells in the grafted tissue, and an increase with time was observed in mouse testis allografts (Schlatt *et al.* 2003), bovine (Rathi *et al.* 2005) and sheep xenografts. It was proposed that this is due to the accumulation of fluid produced by the Sertoli cells because of the absence of efferent duct tissue (Schlatt *et al.* 2003). This could be affecting the rate of sperm production and the fertilizing capacity of spermatozoa recovered from grafts. Therefore, it will be also necessary to study the fertilizing ability of sperm recovered at different time points after grafting.

Xenografting of testis tissue provides a reliable system to obtain spermatozoa from immature animals from a variety of species including domestic bovids such as goats (Honaramooz *et al.* 2002a), bulls (Oatley *et al.* 2004, Rathi *et al.* 2006) and sheep (this study). The spermatozoa isolated from grafts, when used for ICSI, are able to fertilize in pig and goat (Honaramooz *et al.* 2002a), to support embryo development to the blastocyst stage in rhesus monkey (Honaramooz *et al.* 2004) and to develop to term after embryo transfer (ET) in the mouse (Schlatt *et al.* 2003). Therefore, it is anticipated that offspring of the wild species could be produced following this approach, since techniques such as oestrus synchronization, ovarian stimulation and oocyte collection, *in vitro* oocyte maturation, ICSI and ET have been developed for various wild ungulates (Ptak *et al.* 2002, Pukazhenti *et al.* 2006, Roldan *et al.* 2006, Berlinguer *et al.* 2008).

In summary, the present study demonstrated that complete spermatogenesis occurs in sheep tissue

xenografts after 12 weeks post grafting similar to the timing of spermatogenesis in intact animals. Since similar results were reported previously for immature testis tissue from bulls and goats, it is likely that in xenografts of wild bovids elongated spermatids will be formed at the same time as in the intact animal. Furthermore, xenografting of isolated sheep testis cells can regenerate functional testis tissue, and elongated spermatids were presented 40 weeks after grafting. Xenografting of bovid testis or isolated cells may present a novel and important opportunity to preserve male germ plasm from rare or endangered bovid species.

## Materials and Methods

### Donor testicular tissue, ectopic grafting and tissue recovery

#### Testis tissue grafting

Testes were obtained by castration from two unrelated Suffolk lambs (14 days old, born in March) and used as donor tissue for xenografting. After removing the tunica albuginea and rete testis, testis tissue was cut into small fragments (about 1 mm<sup>3</sup>) and maintained in Dulbecco's Modified Eagle's Medium (DMEM, Gibco Invitrogen) on ice until grafting. Male NCR nude mice (7–8 weeks old) were anaesthetized, castrated and during the same procedure eight fragments of donor testis tissue were implanted under the back skin ( $n=12$  mice per donor). Three recipient mice per donor were killed by CO<sub>2</sub> inhalation at 4, 8, 12 and 16 weeks after grafting.

Pieces of donor and control tissue and recovered grafts were fixed in Bouin's solution followed by three changes of 70% ethanol and processed for histology. Seminal vesicle weights were recorded as an indicator of the presence of bioactive testosterone originating from the lamb testis graft.

#### Control tissue

Testis tissue from two unrelated 12-week-old Suffolk rams (born in March) were used as controls to compare the development of the grafts with the testis development *in situ*.

#### Isolated testis cell grafting

Testes from Suffolk lambs were obtained by routine castration of eight unrelated animals (10–19 days old, born in March) and were used as a source of donor testis cells. A single cell suspension of testicular cells was prepared by a two-step enzymatic digestion as previously described (Honaramooz *et al.* 2002b, 2007). After enzymatic dissociation, the cells were filtered through a 40 µm cell strainer to ensure that a single cell suspension was obtained. Aliquots of 50 × 10<sup>6</sup> cells in DMEM were prepared, centrifuged at 1000 *g* for 5 min and pellets were maintained on ice until grafting. To determine the relative percentages of different cell types present in the cell suspension, aliquots of the initial cell suspension were placed in 0.01% poly-L-lysine (Sigma) coated permanox slide chambers (Nalgen NUNC International, Rochester, NY, USA) (5 × 10<sup>5</sup> cells per chamber) for 2 h, fixed in 4%

paraformaldehyde for 30 min and kept in PBS until processing for cell-type-specific immunocytochemistry.

Male NCR nude mice (9 weeks old,  $n=12$ ) were anaesthetized, castrated and during the same surgery they received four transverse linear incisions into the dorsal skin on either side of the midline. In each incision, the skin was gently separated from the muscle and eight cell pellets, aspirated using polyethylene tubing, were gently transplanted under the skin. The incisions were closed with Michel clips (7.5 mm; Miltex, York, PA, USA). Two recipient mice were killed by CO<sub>2</sub> inhalation at 4, 8, 12, 16, 35 and 40 weeks after grafting. In five additional mice, testis cells and tissue were co-grafted. On the right side of each mouse four cell pellets were transplanted, and on the left side, four pieces of testis tissue were grafted. One mouse was killed 16 weeks after surgery, two at 35 weeks and another two at 40 weeks after grafting.

#### Housing of male mice

Testes from two additional unrelated 14-day-old Suffolk lambs (born in March) were used as donor tissue. Male NCR nude mice (8–9 weeks old) were castrated and received eight fragments of donor testis tissue under the back skin ( $n=8$  mice per donor). Eight mice were housed individually on heated (32 °C) shelves and two groups of four mice each were kept together in two cages. All mice were identified and weighed weekly. Food and water were available *ad libitum*. Mice were killed by CO<sub>2</sub> inhalation 13 weeks post grafting.

All animal procedures were performed with approval and under the guidance of the Institutional Animal Care and Use Committee at the University of Pennsylvania.

### Analysis of xenografts

Control, donor and graft tissue were examined using haematoxylin- and eosin-stained tissue sections. All seminiferous tubules present in one section per sample were examined under 200× magnification and classified as (1) Sertoli cells only (Fig. 1A), (2) according to the most advanced type of germ cell present (gonocyte, spermatocytes, round spermatids or elongated spermatids; Fig. 1A and B), (3) as dilated when the height of the seminiferous epithelium was low in comparison with the tubular lumen (Fig. 1B) or (4) as partially degenerated when the cells inside tubules appeared pycnotic and there was no lumen present (Fig. 1B).

To determine the number of pre-meiotic germ cells, in every sample an antibody against PGP 9.5 (also called ubiquitin C-terminal hydrolase L-1) was used, as described by Rodriguez-Sosa *et al.* (2006) with some modifications. Briefly, slides were deparaffinized, treated with 3% H<sub>2</sub>O<sub>2</sub> in distilled water for 10 min, washed twice in PBS for 5 min and blocked with 5% goat serum in PBS for 30 min at room temperature. Sections were then exposed for 10 min to avidin block, washed in PBS for 5 min, exposed to biotin block for 10 min and washed again in PBS for 5 min. Subsequently, the samples were incubated overnight at 4 °C in a humidified chamber with the primary antibody (rabbit anti-PGP 9.5; Biogenesis, Kingston, NH, USA) diluted 1:500 in PBS. The following day samples were washed twice in PBS and treated for 30 min at room temperature with the secondary

antibody, biotinylated goat anti-rabbit IgG (1.5 mg, Vector, Burlingame, CA, USA) diluted to 6 µg/ml in PBS. After washing twice in PBS, the slides were exposed for 30 min to streptavidin horseradish peroxidase (3 µg/ml in PBS, Vector) and washed in PBS for 5 min. Peroxidase activity was detected with VIP (Vector) for 1.5 min, washed for 5 min in distilled water, dried and mounted with Permount. Grafts formed *de novo* from isolated cells were stained as above after citrate antigen retrieval by boiling in Antigen Unmasking Solution (Vector) for 10 min.

To quantify the number of Sertoli cells in the slides with differentiated germ cells present, immunohistochemistry against GATA-binding protein 4 was used with the same protocol described above but with the following modifications: citrate antigen retrieval was performed, CAS block (Zymed Invitrogen) was used as a blocker, incubation with the primary antibody (anti-GATA4, goat polyclonal IgG diluted 1:100 in TBS; Santa Cruz Biotechnology, Santa Cruz, CA, USA) was for 1 h at room temperature and biotinylated donkey anti-goat IgG (Jackson ImmunoResearch, West Grove, PA, USA) was used as the secondary antibody.

At 4 and 8 weeks post grafting, one section per graft was processed for immunohistochemistry for PGP 9.5 and another for GATA4 as described previously. The number of tubules with spermatogonia and the number of spermatogonia and Sertoli cells per tubule were scored in round seminiferous tubule cross-sections at 400× magnification. The number of spermatogonia per 100 Sertoli cells was calculated by dividing the number of spermatogonia per tubule by the number of Sertoli cells per tubule and multiplying by 100.

To assess the relative percentages of different cell types present in the isolated cell suspension, immunocytochemistry was performed with antibodies against VASA (also called MVH/DDX4, mouse VASA homologue/DEAD box polypeptide 4; 2 µg/ml; Abcam, Cambridge, MA, USA) for germ cells, GATA4 (1:40) for Sertoli cells,  $\alpha$ -smooth muscle actin (1:1000, Sigma) for myoid cells and P450 side chain cleavage enzyme (P450sc, 1;200; Chemicon International, Temecula, CA, USA) for Leydig cells following the protocols described in Paul *et al.* (2005) and Honaramooz *et al.* (2007). To stain the spermatogonia in the isolated cell suspension, the antibody against PGP 9.5 was not used to rule out cross-reaction with interstitial cells observed in the tissue slides. Cell-type specificity of the antibodies used was confirmed on paraffin sections of donor sheep testis tissue (Fig. 5).

### Statistical analysis

Statistical analysis was performed with SPSS 12.0 for Windows (SPSS Inc., Chicago, IL, USA). ANOVA and *t*-test for independent samples were performed considering mouse as the experimental unit. When the variables could not be normalized, the corresponding nonparametric analyses, Mann–Whitney and Kruskal–Wallis, were employed. Data are expressed as means  $\pm$  S.E.M.

### Acknowledgements

We thank Dr Jose Rafael Rodríguez-Sosa for his help with immunohistochemistry, Terry Jordan and her staff for animal care, and Jose Benavent-Corai for his help with statistical analyses.

This study was supported by NIH/NCRR RR17359-05, USDA/CS-REES/NRICGP 03-35203-13486 and Spanish Ministry of Education and Science (CGL2006-13340/BOS and BES-2004-4112). The authors declare that there is no conflict of interest that would prejudice the impartiality of this scientific work.

### References

- Arregui L, Rathi R, Zeng W, Honaramooz A, Gomendio M, Roldan ERS & Dobrinski I 2008 Xenografting of adult mammalian testis tissue. *Animal Reproduction Science* **106** 65–76.
- Berlinguer F, González R, Succu S, del Olmo A, Garde JJ, Espeso G, Gomendio M, Ledda S & Roldan ERS 2008 *In vitro* oocyte maturation, fertilization and culture after ovum pick-up in an endangered gazelle (*Gazella dama mhorr*). *Theriogenology* **69** 349–359.
- Dobrinski I, Megee S & Honaramooz A 2003 Xenografting of testis tissue from neonatal ram lambs into mouse hosts accelerates testicular maturation and sperm production. *36th Annual Meeting of the Society for the Study of Reproduction*, Cincinnati, Ohio, USA.
- Dufour JM, Rajotte RV & Korbitt GS 2002 Development of an *in vivo* model to study testicular morphogenesis. *Journal of Andrology* **23** 635–644.
- Fitchett AE, Barnard CJ & Cassaday HJ 2006 There's no place like home: Cage odours and place preference in subordinate CD-1 male mice. *Physiology and Behavior* **87** 955–962.
- Gassei K, Schlatt S & Ehmcke J 2006 *De novo* morphogenesis of seminiferous tubules from dissociated immature rat testicular cells in xenografts. *Journal of Andrology* **27** 611–618.
- Geens M, de Block G, Goossens E, Frederixx V, van Steirteghem A & Tournaye H 2006 Spermatogonial survival after grafting human testicular tissue to immunodeficient mice. *Human Reproduction* **21** 390–396.
- Gier HT & Marion GB 1970 Development of the mammalian testis. In *Development, Anatomy and Physiology*, pp 2–43. Eds AD Johnson, WR Gomes & NL Vandermark. London: Academic Press.
- Hernández Fernández M & Vrba ES 2005 A complete estimate of the phylogenetic relationships in Ruminantia: a dated species-level supertree of the extant ruminants. *Biological Reviews* **80** 269–302.
- Honaramooz A, Snedaker A, Boiani M, Schöler H, Dobrinski I & Schlatt S 2002a Sperm from neonatal mammalian testes grafted in mice. *Nature* **418** 778–781.
- Honaramooz A, Megee SO & Dobrinski I 2002b Germ cell transplantation in pigs. *Biology of Reproduction* **66** 21–28.
- Honaramooz A, Li MW, Penedo MCT, Meyers S & Dobrinski I 2004 Accelerated maturation of primate testis by xenografting into mice. *Biology of Reproduction* **70** 1500–1503.
- Honaramooz A, Zeng W, Rathi R, Koster J, Ryder O & Dobrinski I 2005 193 Testis tissue xenografting to preserve germ cells from a cloned banteng calf. *Reproduction, Fertility and Development* **17** 247.
- Honaramooz A, Megee SO, Rathi R & Dobrinski I 2007 Building a testis – formation of functional testis tissue after transplantation of isolated porcine (*Sus scrofa*) testis cells. *Biology of Reproduction* **76** 43–47.
- Huang S, Sartini BL & Parks JE 2008 Spermatogenesis in testis xenografts grafted from pre-pubertal Holstein bulls is re-established by stem cell or early spermatogonia. *Animal Reproduction Science* **103** 1–12.
- Kita K, Watanabe T, Ohsaka K, Hayashi H, Kubota Y, Nagashima Y, Aoki I, Taniguchi H, Noce T, Inoue K *et al.* 2007 Production of functional spermatids from mouse germline stem cells in ectopically reconstituted seminiferous tubules. *Biology of Reproduction* **76** 211–217.
- Koyama S & Kamimura S 1999 Lowered sperm motility in subordinate social status of mice. *Physiology and Behavior* **65** 665–669.
- Latham N & Mason G 2004 From house mouse to mouse house: the behavioural biology of free-living *Mus musculus* and its implications in the laboratory. *Applied Animal Behaviour Science* **86** 261–289.
- Van Loo PLP, Van de Weerd HA, Van Zutphen LFM & Baumans V 2004 Preference for social contact versus environmental enrichment in male laboratory mice. *Laboratory Animals* **38** 178–188.
- Machida T, Yonezawa Y & Noumura T 1981 Age-associated changes in plasma testosterone levels in male mice and their relation to social dominance or subordination. *Hormones and Behavior* **15** 238–245.



- Oatley JM, de Avila DM, Reeves JJ & McLean DJ** 2004 Spermatogenesis and germ cell transgene expression in xenografted bovine testicular tissue. *Biology of Reproduction* **71** 494–501.
- Oatley JM, Reeves JJ & McLean DJ** 2005 Establishment of spermatogenesis in neonatal bovine testicular tissue following ectopic xenografting varies with donor age. *Biology of Reproduction* **72** 358–364.
- Paris MCJ & Schlatt S** 2007 Ovarian and testicular tissue xenografting: its potential for germline preservation of companion animals, non-domestic and endangered species. *Reproduction, Fertility and Development* **19** 771–782.
- Parks JE, Lee DR, Huang S & Kaproth MT** 2003 Prospects for spermatogenesis *in vitro*. *Theriogenology* **59** 73–86.
- Paul C, Rhind SM, Kyle CE, Scott H, McKinnell C & Sharpe RM** 2005 Cellular and hormonal disruption of fetal testis development in sheep reared on pastured treated with sewage sludge. *Environmental Health Perspectives* **113** 1580–1587.
- Ptak G, Clinton M, Barboni B, Muzzeddu M, Cappai P, Tischner M & Loi P** 2002 Preservation of the wild European mouflon: the first example of genetic management using a complete program of reproductive biotechnologies. *Biology of Reproduction* **66** 796–801.
- Pukazhenthi B, Comizzoli P, Travis AJ & Wildt DE** 2006 Applications of emerging technologies to the study and conservation of threatened and endangered species. *Reproduction, Fertility and Development* **18** 77–190.
- Rathi R, Honaramooz A, Zeng W, Schlatt S & Dobrinski I** 2005 Germ cell fate and seminiferous tubule development in bovine testis xenografts. *Reproduction* **130** 923–929.
- Rathi R, Honaramooz A, Zeng W, Turner R & Dobrinski I** 2006 Germ cell development in equine testis tissue xenografted into mice. *Reproduction* **131** 1–9.
- Rodriguez-Sosa JR, Dobson H & Hahnel A** 2006 Isolation and transplantation of spermatogonia in sheep. *Theriogenology* **66** 2091–2103.
- Roldan ERS, Gomendio M, Garde JJ, Espeso G, Ledda S, Berlinguer F, del Olmo A, Soler AJ, Arregui L, Crespo C *et al.*** 2006 Inbreeding and reproduction in endangered ungulates: preservation of genetic variation through the organization of genetic resource banks. *Reproduction of Domestic Animals* **41** (Suppl 2) 82–92.
- Schlatt S, Kim SS & Gosden R** 2002 Spermatogenesis and steroidogenesis in mouse, hamster and monkey testicular tissue after cryopreservation and heterotopic grafting to castrated hosts. *Reproduction* **124** 339–346.
- Schlatt S, Honaramooz A, Boinai M, Schöler HR & Dobrinski I** 2003 Progeny from sperm obtained after ectopic grafting of neonatal mouse testes. *Biology of Reproduction* **68** 2331–2335.
- Schlatt S, Honaramooz A, Ehmcke J, Goebell PJ, Rübber H, Dhir R, Dobrinski I & Patrizio P** 2006 Limited survival of adult human testicular tissue as ectopic xenograft. *Human Reproduction* **21** 384–389.
- Schmidt JA, de Avila JM & McLean DJ** 2006 Effect of vascular endothelial growth factor and testis tissue culture on spermatogenesis in bovine ectopic testis tissue xenografts. *Biology of Reproduction* **75** 167–175.
- Shinohara T, Inoue K, Ogonuki N, Kanatsu-Shinohara M, Miki H, Nakata K, Kurome M, Nagashima H, Toyokuni S, Kogishi K *et al.*** 2002 Birth of offspring following transplantation of cryopreserved immature pieces and *in vitro* microinsemination. *Human Reproduction* **17** 3039–3045.
- Snedaker AK, Honaramooz A & Dobrinski I** 2004 A game of cat and mouse: xenografting of testis tissue from domestic kittens results in complete cat spermatogenesis in a mouse host. *Journal of Andrology* **25** 926–930.
- Würbel H** 2001 Ideal homes? Housing effects on rodent brain and behaviour *Trends in Neurosciences* **24** 207–211.
- Zeng W, Avelar GF, Rathi R, Franca LR & Dobrinski I** 2006 The length of the spermatogenic cycle is conserved in porcine and ovine testis xenografts. *Journal of Andrology* **27** 527–533.

---

Received 25 September 2007

First decision 30 October 2007

Revised manuscript received 28 February 2008

Accepted 18 March 2008