

## FERTILITY PRESERVATION

**Freezing of ovarian tissue and clinical opportunities**

C Yding Andersen, L S Mamsen and S G Kristensen

Laboratory of Reproductive Biology, The Juliane Marie Centre for Women, Children and Reproduction, Copenhagen University Hospital and Faculty of Health and Medical Sciences, University of Copenhagen, Copenhagen, Denmark

Correspondence should be addressed to C Yding Andersen; Email: [yding@rh.dk](mailto:yding@rh.dk)

This paper forms part of an anniversary issue on Fertility Preservation. The Guest Editor for this section was Professor Roger Gosden, College of William and Mary, Williamsburg, Virginia, USA

**Abstract**

Ovarian tissue cryopreservation (OTC) is mainly used for fertility preservation in girls and women facing a gonadotoxic treatment. If the woman subsequently becomes menopausal, the ovarian tissue may be transplanted to regain ovarian function, including fertility. The method was developed more than two decades ago and today thousands of women worldwide have undergone OTC. Fewer than 500 patients have had tissue transplanted and close to 100% of those regain ovarian function. Several technical aspects of OTC are now becoming more established, including high quantitative follicle survival, defining the size of the tissue resulting in optimal tissue revascularisation and follicle loss resulting from transport of ovarian tissue prior to freezing. We have used OTC to safeguard fertility in patients with genetic diseases, which for some diagnoses is purely experimental, as no transplantations is yet been performed. Usage of OTC beyond fertility is now also being considered; here, the endocrine function of follicles is the focus. It has been suggested that ovarian tissue stored in the reproductive years may be used to avoid premature ovarian insufficiency (POI) when there is a familial disposition or to postpone menopause in patients with an increased risk of osteoporosis or cardiovascular diseases. The benefit of OTC beyond fertility requires, however, actual clinical studies. The current review includes several recent technical aspects with contributions from Denmark building on some of the early work by Roger Gosden.

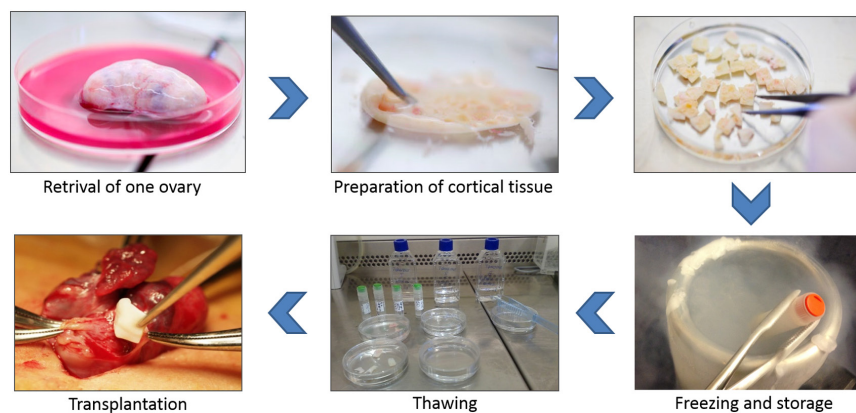
*Reproduction* (2019) **158** F27–F34

**Introduction**

In several countries, ovarian tissue cryopreservation (OTC) has now been performed for more than two decades in a clinical setting, with an aim to save fertility in patients facing an unnaturally accelerated loss of follicles. Currently, it is estimated that more than 10,000 girls and women worldwide have undergone OTC (Donnez & Dolmans 2017, Gellert *et al.* 2018). The procedure involves surgical removal of ovarian tissue followed by freezing of the cortical tissue prepared to a thickness of approximately 1 mm (Fig. 1). The freezing requires introduction of cryoprotectants to avoid ice-crystal formation and damage of cell integrity. Several media and protocols for freezing are currently employed and ovarian cortical tissue and especially the early stages of follicular development appears to be quite resistant to freezing. The tissue is stored in liquid nitrogen, and long-term survival has been demonstrated by similar good survival of follicles after short-term storage and after 17-year period of freezing (Kristensen *et al.* 2018). After thawing, the tissue may be transplanted to the woman from whom it originated. As the cortical tissue primarily contains early stages of follicular development it takes

3–6 months for the tissue to regain full activity including sustaining development of preovulatory follicles and release of fertilisable oocytes. The procedure has moved from being experimental, based mainly on animal studies, to become a robustly validated clinical freezing technique. Laboratory investigations and clinical practice have demonstrated that almost all women regain ovarian function upon transplantation of tissue (Donnez *et al.* 2013, Jensen *et al.* 2015). For obvious reasons, the number of ovarian tissue transplantations (OTT) is much lower than the number of ovaries being frozen: (1) patients need time to recover from their cancer disease and (2) avoid relapse for a period of time; (3) a number of patients are young girls who do not yet wish to reproduce and for whom a storage period of 10–20 years or even longer is expected; (4) a number of women maintain menstrual cycles despite the gonadotoxic treatment they received and may not need the cryopreserved tissue to reproduce and (5) a number of patients may not survive the disease.

OTC was developed for fertility preservation in patients facing gonadotoxic treatment in connection with malignant diseases or in non-malignant conditions



**Figure 1** Cryopreservation of ovarian tissue for fertility preservation. Initially an oophorectomy is performed where one whole ovary or part of an ovary is surgically removed. The medulla is removed, and the cortex is trimmed to a thickness of 1–2 mm and usually cut into pieces with an area of approximately 5 × 5 mm. The pieces of cortex equilibrate in cold freezing solution for 30 min on ice. The cortex pieces are then transferred to individual cryotubes and slow-frozen in liquid nitrogen. Orthotopic transplantation can be performed to restore fertility, and thawed pieces of cortex are placed in subcortical pockets in the remaining ovary.

such as systemic lupus erythematosus, but women with rare genetic diseases have also benefitted from OTC. A summary of the different diagnoses referred to OTC in Denmark in relation to age is depicted in Fig. 2, which overall reflects the relative frequency with which they occur. Cancer diseases are still the main indication for using OTC, but various other diagnoses may also benefit from the technique.

A recent study evaluated the cases of 364 women who underwent OTT and found that more than 95% of all transplanted women experienced renewed or strengthened ovarian function (Gellert *et al.* 2018), demonstrating that the freezing process itself should not be considered experimental any longer. The functional longevity of the tissue is highly variable but depends on the age of the patient at OTC and the size of the ovarian reserve at freezing and on the amount of tissue being transplanted. However, it is remarkable that some women experience ovarian function for extended periods of time (up to 10 years) (Andersen *et al.* 2012), whereas others experience only a relatively short period of ovarian function of 1–2 years (Jensen *et al.* 2015).

Moreover, the safety of transplanting ovarian tissue was evaluated in 264 cases as published in peer-reviewed studies and there has not been any cases reported where the grafted tissue caused relapse of the cancer disease (Gellert *et al.* 2018), except for one case in Australia, where the woman suffered from a granulosa cell tumour that reappeared upon transplantation (Stern *et al.* 2013).

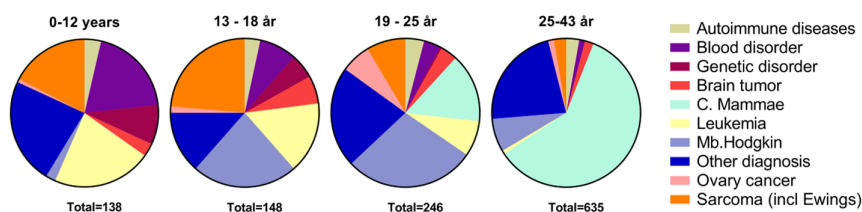
Currently, it has been estimated that more than 130 children worldwide have been conceived from OTT (Jensen *et al.* 2017, Donnez & Dolmans 2017, Gellert *et al.* 2018). Thus, restoration of fertility from frozen/

thawed ovarian tissue is indeed a developing area, which undoubtedly will witness many improvements and new advances. It is tempting to make an analogy to the introduction of the *in vitro* fertilisation (IVF) technique. The number of new methods and introduction of new techniques that have taken place since the first 100 IVF children were born in the early-to-mid 1970s and 1980s are numerous, even though the IVF technique was already established prior to the clinical breakthrough in the early 1980s. Indeed, the IVF success rates increased for several decades after the first IVF baby was born. Freezing of ovarian tissue has the same potential as IVF and may become a widely used technique mainly because the functional unit of the ovary is stored, not only oocytes, which enable restoration of both fertility and the endocrine function, providing options for new uses of the tissue.

The aim of the current review is to highlight current developments for OTC, which has taken place with contributions from our centre in Denmark and which in several instances is a continuation of the work that Roger Gosden initiated in his active carrier. Further we try to outline potential new areas in which this technique can become an asset to girls and women in the coming years.

### Practical aspects of freezing ovarian tissue

In most cases, ovarian tissue is surgically excised just prior to initiation of a gonadotoxic cancer treatment or due to a genetic disease that cause premature depletion of the ovarian reserve. Usually one of the two ovaries are removed, or part of one or both ovaries, and used for fertility preservation. The operation is a laparoscopy procedure performed at day care where the patient



**Figure 2** Diagnoses according to age at OTC in Denmark.

returns home the same day. It is now becoming the norm to remove one entire ovary instead of biopsies from one or two ovaries. One ovary constitutes half of the ovarian reserve and the size of the pool of follicles subsequently transplanted reflects the chance of success and having a sufficient large pool transplanted is an advantage also for longevity of function (Rosendahl *et al.* 2011).

The primordial follicles are located just beneath the ovarian surface in the cortical region, which at any moment in any woman's contains more than 90% of follicles present. This anatomical fact explains why frozen/thawed ovarian tissue can re-establish an ovarian organ function, since each of primordial follicles has the potential to grow to the preovulatory stage. The cortex is isolated to thickness of around 1–2 mm and this thinness makes it possible for the cryoprotectants to penetrate and equilibrate all cells in a relatively short period of time and thereby reduce the cell toxic effects from the low-molecular-weight organic compounds that are essential components of all cryoprotectant mixtures. So, an essential step in all cryo-protocols is to equilibrate the tissue sufficiently, as fast as possible, and thereafter immediately start the freezing process. The freezing process itself is also critical requiring a programmable freezer that can lower the temperature at a rate that allows water to diffuse out of the cells, while the organic solvent to enter the cells before vitrification takes place usually around 30–40 degrees below zero (Jain & Paulson 2006).

The thin cortex is normally cut into pieces with area of 5×5 mm, but this may vary depending on the age of the girl/woman and the size of the ovary, often the pieces in girls have a smaller area of just 3×3 mm, but larger pieces of 15×5 mm may also be prepared that fit better into pockets on either side of the ovary at transplantation. It may be a disadvantage to prepare too small pieces of cortex since such pieces may be difficult to fix to the underlying surface and if they move around after the woman is back to her normal life revascularisation may be hampered leaving the tissue with a lower supply of oxygen and nutrients, which may result in a higher follicle loss.

The advantage of having relatively larger pieces of cortex for transplantation is also one of the main reasons for the slow-freezing technique is preferred over the vitrification technique, which benefits from relatively small pieces of cortex. Currently, it is only a few percent of all children conceived after grafting of frozen/thawed ovarian tissue (i.e. more than 130) that result from vitrified tissue and the vitrification technique is mainly performed in far east Asia (Suzuki *et al.* 2015, Gellert *et al.* 2018).

### Transport of ovarian tissue prior to freezing

To enhance the overall efficacy of OTC and transplantation, we have developed a transport model

where the patient stays and the tissue moves. This model benefits the patients, the referral centre where the ovarian tissue is surgically removed and the central laboratory performing the cryopreservation and storage (Schmidt *et al.* 2003, Duncan *et al.* 2016, Van der Ven *et al.* 2016, Kyono *et al.* 2017). In Denmark, one central laboratory performs OTC for the nation as a whole, and three main university hospitals in different parts of Denmark counsel and inform the patients. If a patient decides to undergo OTC, the tissue will be excised at the local hospital and transported to the central laboratory, where it will be cryopreserved and stored. If the patient requests transplantation, the tissue will be transported in liquid nitrogen to the local hospital and transplanted (Schmidt *et al.* 2011). This system, developed in Denmark, reflects that all aspects of this procedure is covered by the public health care and is free of cost to the patient.

The model was developed to accommodate the needs of the patient, who has just received a devastating and potentially deadly diagnosis, when confronted with the need for fertility preservation. The patient may not be ready or well enough to travel long distances to another hospital on short notice, and if the tissue can be extracted at the local hospital, it will make the procedure more manageable for the patient and allow for a fast initiation of cancer treatment if required.

Although OTC is becoming more widely used, most centres will still see only a limited number of cases annually. This allows clinicians at the referral centre to focus on areas other than fertility preservation as, for instance, IVF procedures, and deal only with fertility preservation patients when needed. The local IVF clinic does not need to focus on maintaining expertise in this relatively seldom performed procedure and can put resources into producing and maintaining up-to-date standard operating procedures (SOPs) as currently required by most national authorities.

In contrast, the central laboratory performing the OTCs will be able to focus on securing adequate training for personnel, maintaining SOPs and undertaking research to advance the technique as such. In Denmark, the central laboratory performs on average two OTCs per week, which corresponds to around 20 OTCs per million inhabitants in Denmark per year. This model has been used for the past 15 years, and more than 1100 OTCs have been performed in which the tissue was transported prior to freezing in 600 of these. In Denmark, transplantation has been performed a total of 130 times, of which 80 were with transported tissue. In all women, the ovarian function was re-established or reinforced if the woman was not completely menopausal. Further, several Danish children have been born from transported, transplanted frozen/thawed ovarian tissue. Recently, it was shown that follicle survival of frozen/thawed tissue transported was similar to that of fresh frozen tissue



(Kristensen *et al.* 2018), demonstrating that the loss of follicles during transportation is minimal.

This transport model has now been found to be valuable in clinical practice and is becoming widely known as the Danish model: 'the woman stays, the tissue moves' (Duncan *et al.* 2016, Kyono *et al.* 2017). The technique has been implemented in other European countries (Germany and Norway) and in Asia. Recently, the model was also used for intercontinental transfer of ovarian tissue prior to freezing.

### Technical aspects of freezing ovarian tissue: defining endpoints

Although OTC has been performed by specialised centres for almost two decades, only relatively few centres have embarked on establishing the technique on a clinical scale. One of the problems in introducing OTC on a wider scale has been the difficulties in defining a uniformly accepted protocol for the cryopreservation procedure. The technique has been improved and we want to focus on the choice of cryoprotectants, the freezing method, the size of the tissue pieces being frozen and the number of pieces being transplanted.

Ovarian tissue can be frozen using a variety of cryoprotectants. The most common ones are ethylene glycol (Schmidt *et al.* 2011) and DMSO (Jadoul *et al.* 2017), although propylene glycol is also used by some centres (Gook 2017). These low-molecular-weight, organic molecules are capable of penetrating cell membranes and are always combined with a non-penetrable sugar molecule (most often sucrose) that facilitates a further reduction in intracellular water activity (Jain & Paulson 2006). Which combinations of these cryoprotectants result in the most efficient survival of primordial follicles has never been resolved.

Further, the freezing process may be performed using either the slow-freezing or the vitrification technique. Which protocol provides the best results has been debated at numerous conferences and in many papers (Isachenko *et al.* 2009, Keros *et al.* 2009, Sanfilippo *et al.* 2015, Suzuki *et al.* 2015). The lack of consensus comes from the absence of suitable methods to determine a clinically relevant endpoint. In contrast to most procedures in conventional assisted reproductive technology (ART), in which a positive human chorionic gonadotropin (hCG) test proves an initial success within a 2-week period, it is difficult to define a suitable endpoint for optimising OTC and transplantation. In OTC, the success in terms of children born is the primary endpoint but can only be determined after the tissue is transplanted. This invariably takes several years after freezing – maybe decades, especially in young girls. After the tissue is transplanted, it takes months before ovarian function is re-established. Several factors affect both the numerator and the denominator in calculating

success for OTC and transplantation, which currently complicates a direct evaluation of the efficacy (Yding Andersen 2015). The time to pregnancy varies greatly; in the Danish cohort, we have found that although some women with transplanted ovarian tissue become spontaneously pregnant, others spend more than 5 years in ART treatment to achieve a pregnancy. Further, it can be difficult to keep track of patients many years after treatment ends, and the outcome might not be readily available. Basically, it is impossible to calculate a precise success rate comparable to most conventional IVF procedures. Thus, surrogate endpoints must be employed to evaluate the efficacy of the freezing procedure and the fertility potential that are introduced by grafting. The second-best endpoint after children born from the procedure is likely the functional duration of the tissue following transplantation, but this endpoint obviously has the same weakness as the primary outcome; it will take many years before any results will emerge. Furthermore, until recently, there has been no method to evaluate follicle survival quantitatively during the freezing process. Therefore, weaker but more readily available endpoints such as follicle morphology after thawing, hormone production from thawed tissue or gene expression of molecular markers in the thawed tissue can be used to optimise the OTC protocols.

Recently, a new method based on the vital dye neutral red that evaluates the quantitative survival of follicles following freezing and thawing was published (Kristensen *et al.* 2018). This is only an *in vitro* test that is only used to determine follicle survival in tissue which is not transplanted back to the woman. Thus, the neutral red method is suited to evaluate the efficacy of the freezing process and not in a clinical setting. This method has now addressed the shortcomings of defining suitable endpoints as described in the previous section. Neutral red was shown to accumulate in living follicles, giving them an intense red staining (Fig. 3), whereas nonviable follicles remained unstained (Chambers *et al.* 2010, Kristensen *et al.* 2011, 2018, Duncan *et al.* 2016, Morewood *et al.* 2017). Thus, frozen/thawed ovarian tissue cut into small fragments could be incubated in a neutral red solution that stained viable follicles with an intense dark red colour (Fig. 3), and pieces in which the number of follicles stained red could be clearly identified, counted, collected and processed for histology. Previous studies showed that only viable follicles take up the dye (Kristensen *et al.* 2011). Histologically, the total number of follicles were counted and related to the number of viable follicles counted directly, providing a follicular survival rate. The average of 5–10 individual tissue pieces (with varying numbers of follicles) determined the survival rate. In fresh, unfrozen ovarian tissue, the survival rate was 91%, and the survival rate from 25 individual frozen/thawed ovarian samples was consistently high, with an average of 84% survival (Kristensen *et al.* 2018). This clearly



**Figure 3** (A) A fresh ovarian biopsy. PAS-stained human ovarian cortex showing early-stage resting follicles located within the tissue. (B) Thawed pieces of human ovarian cortex ( $5 \times 5 \times 1-2$  mm). (C) Viability assessment. Frozen-thawed human ovarian cortical tissue stained with neutral red for 3–4 h *in situ*. Red stained viable follicles are located within the tissue.

demonstrated that the majority of follicles survive the slow freeze procedure. In addition, the survival rate of follicles that had been stored in liquid nitrogen for up to 17 years was similar to that stored for tissue stored for just a few years. Currently, no study of slow freezing and vitrification compares follicle survival while using the new neutral red staining method. Irrespective of the outcome of such a comparison, the follicle survival rate is so high that further improvements should focus on refining the transplantation techniques.

Obviously, for a woman to benefit from OTC, the tissue needs to be transplanted, and this process is probably more devastating to follicle survival than the freezing procedure. A previous study in sheep showed that up to two-thirds of all follicles are lost during transplantation, including during the subsequent days after transplantation before revascularisation is established (Baird *et al.* 1999). This study found that only a small fraction of follicles was lost due to the freezing process, which corresponds with our results in human tissue (Kristensen *et al.* 2018). Thus, techniques to improve transplantation, including reperfusion, supply of oxygen and nutrients and reduce apoptosis of the transplanted follicles are keys to increasing the number of surviving follicles that subsequently become available to women and sustain ovarian function in terms of both fertility and duration of function.

### Small versus large pieces of ovarian tissue

Another aspect to augment the total number of surviving follicles following grafting is probably the sizes of the transplanted cortical tissue pieces. The pieces may become too small (less than around  $1-2 \text{ mm}^3$ ), which complicates a firm, steady positioning of the tissue to prevent it from moving as the woman becomes active after transplantation. If small pieces of tissue are left free, floating in a peritoneal pocket or in a pocket below the cortical surface of the existing ovary, it may move as the woman becomes physically active. These movements may disrupt new vessels sprouting into the tissue and thereby prolong the period without vital nutrients and oxygen and consequently reduce follicle survival. Reducing movements of the transplanted tissue may be one method to increase follicle survival. Larger pieces of cortical tissue (around  $5 \times 5 \times 1$  mm) are more easily positioned and fixed to the underlying surface, which will reduce the likelihood of post-transplantation

tissue movements. Thus, faster and more efficient vascularisation and supply of nutrients and oxygen can take place and facilitate better follicle survival.

One study indirectly addressed this concept. Dror Meirou and colleagues excised cortical biopsies from both ovaries, which were frozen from one patient (Meirou *et al.* 2005). At grafting, relatively large pieces of tissue were positioned in one ovary, and small cubes of tissue were placed in the other ovary. The large pieces of tissue were firmly fixed to the underlying surface in subcortical pockets, whereas the small ones were deposited free floating in subcortical pockets. Follicular activity was observed only in the ovary where the larger cortical pieces were transplanted. Preliminary reports from other studies in which *in vitro* follicle activation was attempted by cutting ovarian cortical tissue in small pieces (around  $1 \text{ mm}^3$ ) to activate follicular development by the Hippo signalling pathway with subsequent transplantation have shown similar poor outcome in terms of stimulating follicular growth (Lunding *et al.* 2019).

Taken together, two important questions in connection with OTC have recently been advanced: (1) The slow-freezing technique, using a medium composed of ethylene glycol and sucrose, provides a reduction in viable follicles of less than 10%, based on neutral red staining. It is likely that medium containing DMSO will provide similarly good results, but this needs to be determined. (2) The size of cortical tissue pieces should be large enough to be placed flat on the underlying surface and prevent movement of the tissue when the woman is up and active after the operation.

### Genetic diseases that may have a negative impact on ovarian function

Patients with genetic disorders who are likely to experience accelerated follicle depletion may also be referred for OTC. A summary of the diagnoses of women who have undergone OTC in Denmark is listed in Table 1.

Women with genetic diseases, who might benefit from OTC, can be divided into two groups: (1) those with diseases such as thalassemia, sickle cell anaemia and Fanconi anaemia that require bone marrow transplantation, which is likely to destroy ovarian function, and (2) disorders that themselves pose a risk of follicular depletion, such as Turner syndrome and galactosemia (Mamsen *et al.* 2018, 2019).

**Table 1** Danish patients with rare genetic diseases who have received ovarian tissue freezing to for fertility preservation.

Diagnose	No. patients	Mean age (years, range)	Mean no. of cortex pieces (range)	FSH (IU/L)	LH (IU/L)
				n*, Mean (range)	n*, Mean (range)
Thalassemia	11	10.8 (2.8–17.4)	14 (3–26)	NA	NA
POI	8	23.3 (17.5–27.3)	17 (17–27)	2, 8.9 (8.4–9.3)	2, 5.4 (3.7–7.0)
Turner syndrome	7	15.5 (8.8–22.4)	18 (12–29)	7, 8.9 (2.0–31.0)	7, 5.7 (1.0–17.6)
Galactosemia	6	3.8 (0.3–11.7)	7 (3–13)	1, 19.7	1, 0.6
Sickle cell anaemia	3	11.4 (9.0–16.0)	23 (15–34)	1, 2.0	1, 0.3
Fanconi anaemia	2	8.7 (6.9–10.5)	10 (9–11)	1, 4.2	NA
XXY/X0 mosaic	2	11.6 (6.5–16.6)	4 (3–4)	2, 25.2 (5.4–45.0)	2, 6.8 (0.3–13.2)
XY phenotypic girl	2	8.6 (1.6–15.5)	10 (4–15)	NA	NA
Osteopetrosis	1	11.0	22	NA	NA

Diagnose, number of patients, age, no. of the ovarian cortex pieces cryopreserved.

n\*, number of patient where serum hormone concentrations were available; NA, not available.

Transplantations have not yet been performed in this second group of patients; OTC in this group is truly experimental, and the potential benefits must await actual transplantations.

However, in girls receiving OTC due to thalassemia, the functionality of transplanted tissue has been proven (Matthews *et al.* 2018). Two girls who had the tissue excised at 9 years of age both regained ovarian function and one of them conceived and delivered a healthy child from the transplanted tissue; this patient was also, at tissue harvest, the first truly prepubertal patient to conceive and deliver a healthy child later (Matthews *et al.* 2018).

A special group is composed of women with familial disposition toward POI, which often has a genetic background. Here, OTC may serve two functions, namely, to secure fertility and/or to extend menstrual cycles and a natural endocrine milieu.

### Ovarian tissue freezing for social reasons, including postponing menopause

A reduced birth rate and delaying childbearing are characterising many Western countries. Many well-educated single women now want to preserve their fertility potential by egg banking for nonmedical purposes and postpone family planning until they find the right partner. To improve their chances for having a baby, they will freeze potentially good-quality oocytes at an earlier age. Most of these women will be normally fertile and will freeze oocytes as insurance. This method is now even supported by some companies, and the authorities in some areas of Japan have started to support young women wanting to store oocytes for later use. This obviously reflects the fact that many societies now desperately need to secure replenishment of an ageing population while many young women focus on their careers or consider their chances of providing for their child as they want as unattainable (e.g., education-wise and/or economically), so they choose to postpone motherhood to an advanced age when it may no longer be biologically achievable.

Although this tendency is only starting to emerge, oocyte banking for nonmedical purposes is gaining ground in many Western countries. However, it has been clear for some time that only a small fraction of the oocytes stored for nonmedical purposes will ever be used by the woman herself (Ben-Rafael 2018). Either she is not infertile when she meets her partner or she does not meet him at all. It has recently been estimated that the usage rate of the stored oocytes is as low as 3–9% (Cobo *et al.* 2016, Hammarberg *et al.* 2017, Ben-Rafael 2018), showing that the vast majority of these oocytes will not be used for fertility. This calls for alternative solutions for these women. We have suggested that OTC with its preservation of the huge supply of primordial follicles is an alternative solution. If the woman needs the tissue for fertility it can be grafted, and she may conceive naturally or undergo IVF treatment. If the woman will not use the stored tissue for fertility, which indeed is the most likely scenario, she may use the tissue for endocrine purposes: to postpone menopause or use it to avoid POI. This is a new, unproven suggestion and several questions need further investigation, such as how much tissue should be excised to provide at least some years of continued menstrual cycles and whether the procedure might harm the residual ovarian reserve. These questions are likely to be addressed soon and maybe this option will be of interest to some women, given that the statistical chances of using banked oocytes are marginal.

Preserving ovarian function by freezing ovarian tissue differs from oocyte vitrification mainly in two ways: OTC preserves the functional unit of the ovary including normal endocrine properties, and a high number of resting primordial follicles, which at any age is many times higher than the number of antral follicles. These early-stage follicles do not necessarily contain high-quality oocytes, but they maintain the capacity to sustain hormone production in a quality and a quantity approaching normal preovulatory follicles. These characteristics open new opportunities to improve not only fertility but also quality of life for women who may benefit from a continued endogenous hormone production, such as for women with POI.



We therefore envision this method used in several kinds of clinical settings in which surgery of the ovary is performed, such as for women with endometriosis, polycystic ovary syndrome (PCOS) or a risk of POI (Kristensen & Yding Andersen 2018) and in other situations as well. In the future, women undergoing caesarean section, who are anaesthetised anyway, may want to have a small ovarian biopsy taken during the operation while there is free access to the ovaries and have it frozen for future use.

## Conclusion

It is becoming clear that OTC is a method with several purposes, including both fertility and continued hormone production that may be used in many kinds of clinical situations. OTC may be used beyond for fertility, and the coming years will hopefully show beneficial effects of OTC in many other aspects. We therefore suggest leaving the term 'oncofertility', because the technique encompasses several areas other than cancer. Further hormonal secretion may also be the desired effect in other situations and, therefore, the term 'fertility' does not cover the intended use. We propose to use the term 'cryopreservation of ovarian follicular function (COFF)'.

It has now been demonstrated that the freezing process itself is robust with good follicular survival rates, whereas the grafting procedure leads to substantial follicle loss and attenuated ovarian reserve. Future research should focus on optimising the grafting procedure. Frozen ovaries from truly prepubertal girls appear to function normally after transplantation in adulthood and support fertility. The technical aspects of OTC, including follicle survival from freezing/thawing and fragment size, is now slowly becoming more standardised, and the freezing technique is, in our opinion, beyond the experimental stage.

## Declaration of interest

The authors declare that there is no conflict of interest that could be perceived as prejudicing the impartiality of the research reported.

## Funding

This work was supported by the University Hospital of Copenhagen, the EU interregional project ReproUnion and the Novo Nordic Foundation. They had no role in the study design, collection and analysis of data, data interpretation or production of the report.

## Acknowledgement

All personnel, including those in the clinical activities of fertility preservation, are thanked for their passionate work.

## References

- Andersen CY, Silber SJ, Berghold SH, Jorgensen JS & Ernst E 2012 Long-term duration of function of ovarian tissue transplants: case reports. *Reproductive BioMedicine Online* **25** 128–132. (<https://doi.org/10.1016/j.rbmo.2012.03.014>)
- Baird DT, Webb R, Campbell BK, Harkness LM & Gosden RG 1999 Long-term ovarian function in sheep after ovariectomy and transplantation of autografts stored at –196 C. *Endocrinology* **140** 462–471. (<https://doi.org/10.1210/endo.140.1.6453>)
- Ben-Rafael Z 2018 The dilemma of social oocyte freezing: usage rate is too low to make it cost-effective. *Reproductive BioMedicine Online* **37** 443–448. (<https://doi.org/10.1016/j.rbmo.2018.06.024>)
- Chambers EL, Gosden RG, Yap C & Picton HM 2010 In situ identification of follicles in ovarian cortex as a tool for quantifying follicle density, viability and developmental potential in strategies to preserve female fertility. *Human Reproduction* **25** 2559–2568. (<https://doi.org/10.1093/humrep/deq192>)
- Cobo A, García-Velasco JA, Coello A, Domingo J, Pellicer A & Remohí J 2016 Oocyte vitrification as an efficient option for elective fertility preservation. *Fertility and Sterility* **105** 755–764. (<https://doi.org/10.1016/j.fertnstert.2015.11.027>)
- Donnez J & Dolmans MM 2017 Fertility preservation in women. *New England Journal of Medicine* **377** 1657–1665. (<https://doi.org/10.1056/NEJMr1614676>)
- Donnez J, Dolmans MM, Pellicer A, Diaz-Garcia C, Sanchez Serrano M, Schmidt KT, Ernst E, Luyckx V & Andersen CY 2013 Restoration of ovarian activity and pregnancy after transplantation of cryopreserved ovarian tissue: a review of 60 cases of reimplantation. *Fertility and Sterility* **99** 1503–1513. (<https://doi.org/10.1016/j.fertnstert.2013.03.030>)
- Duncan FE, Zelinski M, Gunn AH, Pahnke JE, O'Neill CL, Songsasen N, Woodruff RI & Woodruff TK 2016 Ovarian tissue transport to expand access to fertility preservation: from animals to clinical practice. *Reproduction* **152** 201–210. (<https://doi.org/10.1530/REP-15-0598>)
- Gellert SE, Pors SE, Kristensen SG, Bay-Björn AM, Ernst E & Yding Andersen C 2018 Transplantation of frozen-thawed ovarian tissue: an update on worldwide activity published in peer-reviewed papers and on the Danish cohort. *Journal of Assisted Reproduction and Genetics* **35** 561–570. (<https://doi.org/10.1007/s10815-018-1144-2>)
- Gook DA 2017 Human ovarian tissue slow freezing. *Methods in Molecular Biology* **1568** 161–176.
- Hammarberg K, Kirkman M, Pritchard N, Hickey M, Peate M, McBain J, Agresta F, Bayly C & Fisher J 2017 Reproductive experiences of women who cryopreserved oocytes for non-medical reasons. *Human Reproduction* **32** 575–581.
- Isachenko V, Lapidus I, Isachenko E, Krivokharchenko A, Kreinberg R, Woriedh M, Bader M & Weiss JM 2009 Human ovarian tissue vitrification versus conventional freezing: morphological, endocrinological, and molecular biological evaluation. *Reproduction* **138** 319–327. (<https://doi.org/10.1530/REP-09-0039>)
- Jain JK & Paulson RJ 2006 Oocyte cryopreservation. *Fertility and Sterility* **86** 1037–1046. (<https://doi.org/10.1016/j.fertnstert.2006.07.1478>)
- Jensen AK, Kristensen SG, Macklon KT, Jeppesen JV, Fedder J, Ernst E & Andersen CY 2015 Outcomes of transplantations of cryopreserved ovarian tissue to 41 women in Denmark. *Human Reproduction* **30** 2838–45. (<https://doi.org/10.1093/humrep/dev230>)
- Jensen AK, Macklon KTL, Fedder J, Ernst E & Andersen CY 2017 86 successful births and 9 ongoing pregnancies worldwide in women transplanted with cryopreserved frozen-thawed ovarian tissue: focus on birth and perinatal outcome in 40 of these children births. *Journal of Assisted Reproduction and Genetics* **34** 325–336. (<https://doi.org/10.1007/s10815-016-0843-9>)
- Jadoul P, Guilmain A, Squifflet J, Luyckx M, Votino R, Wyna C & Dolmans MM 2017 Efficacy of ovarian tissue cryopreservation for fertility preservation: lessons learned from 545 cases. *Human Reproduction* **32** 1046–1054. (<https://doi.org/10.1093/humrep/dex040>)
- Keros V, Xella S, Hultenby K, Pettersson K, Sheikhi M, Volpe A, Hreinsson J & Hovatta O 2009 Vitrification versus controlled-rate freezing in cryopreservation of human ovarian tissue. *Human Reproduction* **24** 1670–1683. (<https://doi.org/10.1093/humrep/dep079>)
- Kristensen SG, Rasmussen A, Byskov AG & Andersen CY 2011 Isolation of preantral follicles from human ovarian medulla tissue. *Human Reproduction* **26** 157–166. (<https://doi.org/10.1093/humrep/deq318>)

- Kristensen SG, Liu Q, Mamsen LS, Greve T, Pors SE, Bjørn AB, Ernst E, Macklon TK & Andersen CY** 2018 A simple method to quantify follicle survival in cryopreserved human ovarian tissue. *Human Reproduction* **33** 2276–2284.
- Kristensen SG & Andersen CY** 2018 Cryopreservation of ovarian tissue: opportunities beyond fertility preservation and a positive view into future. *Frontiers in Endocrinology* **9** 347. (<https://doi.org/10.3389/fendo.2018.00347>)
- Kyono K, Hashimoto T, Toya M, Koizumi M, Sasaki C, Shibasaki S, Aono N, Pinborg N, Nakamura Y, Obata R, Okuyama N et al.** 2017 A transportation network for human ovarian tissue is indispensable to success for fertility preservation. *Journal of Assisted Reproduction and Genetics* **34** 1469–1474. (<https://doi.org/10.1007/s10815-017-1022-3>)
- Lunding SA, Pors SE, Kristensen SG, Landersø SK, Jeppesen JV, Flachs EM, Pinborg A, Macklon KT, Pedersen AT, Andersen CY et al.** 2019 Biopsying, fragmentation and autotransplantation of fresh ovarian cortical tissue in infertile women with diminished ovarian reserve. *Human Reproduction* Epub. (<https://doi.org/10.1093/humrep/dez152>)
- Mamsen LS, Kelsey TW, Ernst E, Macklon KT, Lund AM & Andersen CY** 2018 Cryopreservation of ovarian tissue may be considered in young girls with galactosemia. *Journal of Assisted Reproduction and Genetics* **35** 1209–1217. (<https://doi.org/10.1007/s10815-018-1209-2>)
- Mamsen LS, Charkiewicz K, Anderson RA, Telfer EE, McLaughlin M, Kelsey TW, Kristensen SG, Gook DA, Ernst E & Andersen CY** 2019 Characterization of follicles in girls and young women with Turner syndrome who underwent ovarian tissue cryopreservation. *Fertility and Sterility* **111** 1217.e3–1225.e3.
- Matthews SJ, Picton HM, Ernst E & Andersen CY** 2018 Successful pregnancy in a woman previously suffering from  $\beta$ -thalassaemia following transplantation of ovarian tissue cryopreserved before puberty. *Minerva Ginecologica* **70** 432–435.
- Meirow D, Levron J, Eldar-Geva T, Hardan I, Fridman E, Zalel Y, Schiff E & Dor J** 2005 Pregnancy after transplantation of cryopreserved ovarian tissue in a patient with ovarian failure after chemotherapy. *New England Journal of Medicine* **353** 318–321. (<https://doi.org/10.1056/NEJMc055237>)
- Morewood T, Getreu N, Fuller B, Morris J & Hardiman P** 2017 The effect of thawing protocols on follicle conservation in human ovarian tissue cryopreservation. *Cryo Letters* **38** 137–144.
- Rosendahl M, Schmidt KT, Ernst E, Rasmussen PE, Loft A, Byskov AG, Nyboe Andersen A, Yding Andersen C** 2011 Cryopreservation of ovarian tissue for a decade in Denmark – an overview of the technique. *Reproductive Medicine Online* **22** 162–171. (<https://doi.org/10.1016/j.rbmo.2010.10.015>)
- Sanfilippo S, Canis M, Smitz J, Sion B, Darcha C, Janny L & Brugnion F** 2015 Vitrification of human ovarian tissue: a practical and relevant alternative to slow freezing. *Reproductive Biology and Endocrinology* **13** 1–7. (<https://doi.org/10.1186/1477-7827-13-1>)
- Schmidt KL, Ernst E, Byskov AG, Nyboe Andersen A & Andersen CY** 2003 Survival of primordial follicles following prolonged transportation of ovarian tissue prior to cryopreservation. *Human Reproduction* **18** 2654–2659. (<https://doi.org/10.1093/humrep/deg500>)
- Schmidt KT, Rosendahl M, Ernst E, Loft A, Andersen AN, Dueholm M, Ottosen C & Andersen CY** 2011 Autotransplantation of cryopreserved ovarian tissue in 12 women with chemotherapy-induced premature ovarian failure: the Danish experience. *Fertility and Sterility* **95** 695–701. (<https://doi.org/10.1016/j.fertnstert.2010.07.1080>)
- Stern CJ, Gook D, Hale LG, Agresta F, Oldham J, Rozen G & Jobling T** 2013 First reported clinical pregnancy following heterotopic grafting of cryopreserved ovarian tissue in a woman after a bilateral oophorectomy. *Human Reproduction* **28** 2996–2999. (<https://doi.org/10.1093/humrep/det360>)
- Suzuki N, Yoshioka N, Takae S, Sugishita Y, Tamura M, Hashimoto S, Morimoto Y & Kawamura K** 2015 Successful fertility preservation following ovarian tissue vitrification in patients with primary ovarian insufficiency. *Human Reproduction* **30** 608–615. (<https://doi.org/10.1093/humrep/deu353>)
- Van der Ven H, Liebenthron J, Beckmann M, Toth B, Korell M, Krüssel J, Frambach T, Kupka M, Hohl MK, Winkler-Crepaz K et al.** 2016 Ninety-five orthotopic transplantations in 74 women of ovarian tissue after cytotoxic treatment in a fertility preservation network: tissue activity, pregnancy and delivery rates. *Human Reproduction* **31** 2031–2041. (<https://doi.org/10.1093/humrep/dew165>)
- Yding Andersen C** 2015 Success and challenges in fertility preservation after ovarian tissue grafting. *Lancet* **385** 1947–1948. ([https://doi.org/10.1016/S0140-6736\(15\)60960-6](https://doi.org/10.1016/S0140-6736(15)60960-6))

---

Received 14 December 2018

First decision 8 February 2019

Revised manuscript received 21 June 2019

Accepted 8 July 2019